

# Department of Orthopaedics & Traumatology



THE UNIVERSITY OF HONG KONG  
**CENTENARY**  
香港大學百周年

## Queen Mary Hospital



# The University of Hong Kong Medical Centre

## TABLE OF CONTENTS

### P.1

Message from the Editorial Board

"Doc! I've got a lump on my leg!"

### P.2-3

Management of Soft Tissue Tumour and Sarcoma

### P.4

A Chat with Dr. Lam Ying Lee

Division of General Orthopaedics & Oncology

### P.5

Department Research Day

8th HK International Orthopaedic Forum

### P.6

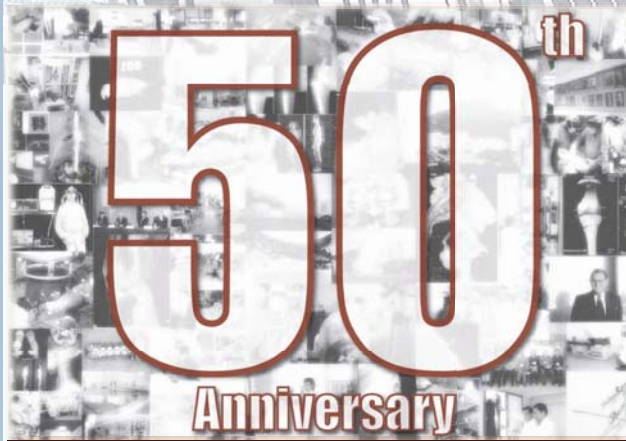Tips from our Allied Health - Amputee Running

### P.6-7

Our Postgraduate Students

### P.8

Announcements  
Forthcoming Events



## Message from the Editorial Board

"Transcend the past, Create the future". Our Department is celebrating its 50th Anniversary this year. To make this a memorable event, a series of activities will be held throughout the year. One of the most important events will be the Hong Kong International Orthopaedic Forum which will be held on 18-21 Aug 2011. You can refer to our website (<http://www.hku.hk/ortho/ortho/>) for the latest update.

While we are celebrating this very important event of the Department, we have not forgotten our recent loss of our beloved Prof. Arthur Yau who had contributed so much to the development of our Department. Attached is our special tribute to Prof. Arthur Yau which was published online earlier.

We hope you will enjoy this issue of our Newsletter and we certainly hope to see you at the Hong Kong International Orthopaedic Forum in August 2011.

## *Doc, I've got a lump on my leg. Should I just get it out?*

**Dr. Ho Wai Yip**

A 35 years old lady presented initially with a slow progressing 3cm painless mass over the anterior aspect of the left upper thigh. USG examination showed a 5cm mass over the anteromedial aspect of the left upper thigh, just next to the superficial femoral vessels. The mass was removed partially by piecemeal and histological examination subsequently showed poorly differentiated synovial sarcoma. The tumour was also found to have extended further (Fig 1). She was referred to our centre for further management.

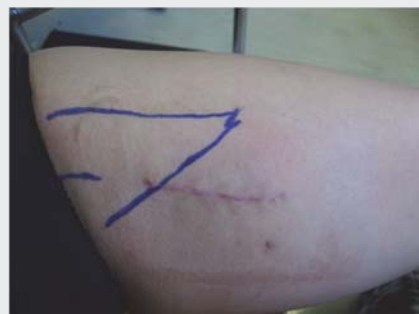

Fig 1 Before the re-excision: note that the drain exit site was far away from the main wound, requiring more extensive sacrifice of skin and soft tissue

On the first assessment, the patient was found to be suffering from deep vein thrombosis of the femoral

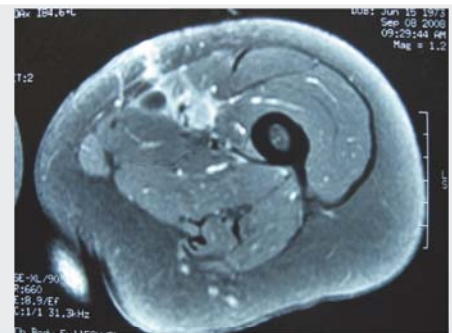


Fig 2: MRI after the first excision: the femoral vessels were surrounded by residual tumour, post-operative haematoma and seroma, necessitating excision of a segment of vascular bundles

vein requiring medical treatment. MRI of the left thigh was arranged and reviewed the encasement of the superficial femoral vessels by residual tumour & post-operative seroma (Fig 2). PET-CT did not identify any distant metastasis.

To salvage the situation, an en bloc wound re-excision with a wide margin was performed. It involved the removal of substantial amount of skin and muscles, as well as a segment of the femoral artery and veins. The femoral artery was reconstructed with artificial graft by our vascular surgeon (Fig 3). Luckily, there was an adequate

amount of skin for primary closure. After the operation, she was given adjuvant radiotherapy for better local disease control. The pathology report of the resected specimen showed tumour-free resective margin.

The patient did not have any local recurrence, but was found to have multiple lung metastases about one year after the re-excision. She received a course of palliative chemotherapy but only survived for another year.

Soft tissue lumps and bumps are a common symptom of patients seeking medical advice from Orthopaedic Surgeons / General Surgeons. One of the pitfalls in managing these masses is mistaking a malignant sarcoma as a benign tumour, resulting in inadequate pre-operative investigations, incomplete excision of the mass, hence leaving a residual tumour inside one's body. This group of patients generally have poorer prognosis, especially those with macroscopic residual tumour. Moreover, their subsequent salvage re-excision surgeries are much more debilitating compared with those who undergo a virgin wide resection of the tumour.

The above case illustrated the breaching of some important oncological principles. Firstly, any mass that is either (1) larger than 5cm, (2) deep to the deep fascia, or (3) rapidly enlarging should alert the attending surgeon about the possibility of a malignant soft tissue sarcoma. It needs to be properly investigated before deciding on the definitive surgical treatment. MRI examination with contrast is a must for localization of the mass, and a properly planned tru-cut or open incisional biopsy for histological diagnosis. One should resist the temptation or pressure from the patient to perform a one stage excision of a potentially malignant soft tissue mass. Intra-operative frozen section is not a reliable tool in confirming the histological diagnosis.

It is important to note that the biopsy tract is considered to be contaminated with tumour cells. It has to be removed with a wide margin with the tumour en bloc. Hence, the site of the biopsy has to be carefully planned.

The standard treatment of a soft tissue sarcoma is wide resection, meaning an en bloc removal of the tumour together with a layer of normal tissue. The tumour is not exposed or visualized during the whole surgical procedure. Piecemeal excision, as in the above case, is bound to leave tumour cells (macroscopic in size) behind.

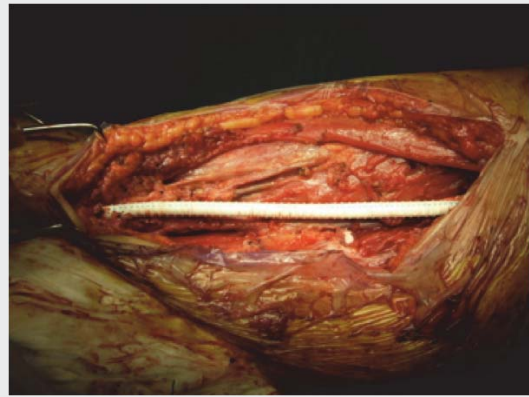


Fig 3: Vascular reconstruction by artificial graft

Chemotherapy is of doubtful benefit and radiotherapy is only useful in eradicating microscopic tumour. An inadequate surgical excision therefore cannot be compensated by other treatment modalities.

The case illustrates the sequelae of an improperly planned excision of a soft tissue sarcoma. To salvage the situation, a larger amount of skin and soft tissue had to be removed. More importantly, we had to sacrifice a segment of the major vascular bundle, requiring more complex reconstruction with higher morbidity. Without the first surgery, the patient had a much higher chance of sparing the femoral vessels.

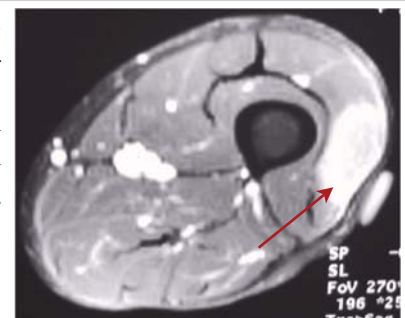
Soft tissue sarcoma can be one of the differential diagnoses in patients presenting with a lump over the extremity. It is therefore important to know the "at-risk" signs and perform proper investigations before deciding on the surgical treatment. If a soft tissue sarcoma is suspected, one can refer the patient to the musculoskeletal tumour centre for further assessment and management. If a soft tissue sarcoma is mistaken as a benign lump and excised with inadequate margin, it is also recommended to refer the patient to musculoskeletal oncologists for consideration of re-excision, which may be the only hope of survival. Reviews from well-renowned tumour centres show that although the re-excision surgery is more difficult and debilitating, the oncological outcome is still reasonable.

## Management of Soft Tissue Tumour & Sarcoma

**Dr. Lam Ying Lee**

The international rate of soft tissue sarcoma ranges from 1.8 to 5.0 cases per 100,000 per year. The Hong Kong incidence is less than 200 cases per year. Malignancy only accounts for 1% of all soft tissue tumours presenting to medical doctors. Only one third of sarcoma patients have pain. The course of the condition may be quite indolent in the early phase for some sarcoma such as synovial sarcoma. After one to two years, it may go into accelerated phase. As a result, these characteristics may mislead patients, primary care physicians, general surgeons or even orthopaedic surgeons in management of the condition. Last year,

47% of our cases were referred after incomplete excision. This was not very different from my report in HKMJ 2004 (1).



Contrast enhanced lesion was shown up in the MRI scan of thigh (red arrow)

In order to minimize this "mismanagement", NICE 2006(2) recommended looking out for features suggestive of malignancy. Any lesion 1) more than 5 cm, 2) progressively increasing in size, 3) deep to the fascia or 4) pain warrants further investigation. The duration of the symptom is not considered a criterion to exclude



malignancy. We had a lady who carried a non-progressive buttock mass for more than 20 years. Eventually, she received medical attention. It later turned out to be a low grade sarcoma.

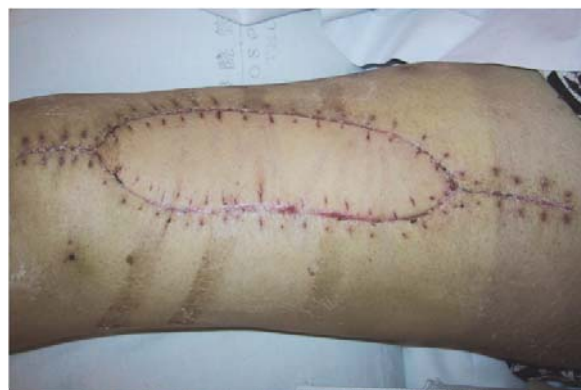For any suspicious lesion, an MRI scan is the gold standard to start the investigation(3). Most of the time, MRI scans cannot tell the exact pathology. Only a few conditions such as ganglion or bursa can be accurately diagnosed by an MRI scan. The hyperintense T1 signal may indicate a tumour with fat content such as lipomatous lesion or haemangioma. The hyperintense T2 signal may reflect edema which can be found in a tumour or infection.

Traditionally, there are other investigations for soft tissue tumour. Nowadays, MRI scans have almost replaced the use of ultrasound studies. Unless it is to confirm a ganglion or to diagnose muscle tear, we rarely order ultrasound studies for soft tissue mass. Most of the time, it just delays the process of diagnosis and wastes time and money. However, ultrasound can be a very important tool in imaging- guided- percutaneous biopsy. With experience, it can lead the biopsy needle to the most representative area and avoid neurovascular bundle contamination.

CT scans of the thorax and bone scans are very important for staging of the condition. For diagnosis of local lesions, contrasted CT scans may be useful in infection and abscesses. They are also the first choice for patients with cardiac pacing because MRI scans cannot be performed. Angiogram is not the optimal choice for soft tissue sarcoma. If vascular lesions such as arterio-venous malformation, or pseudo-aneurysm are suspected, we may consider an MR angiogram which is much less invasive. A PET (positron emission tomography) scan is a functional imaging scan to assess the physiological activity of the tissue. There is still controversy over whether it can safely delineate the benign lesion from the malignant one. Therefore it is not yet good enough to replace biopsy.

We recommend biopsy for any significant lesion before definitive surgery, i.e. a staged surgery. Sometimes, there is pressure from patients because they would rather have only one surgical procedure. An explanation for the importance of patience is the only way to avoid a catastrophic outcome from incomplete resection. Before biopsy, it is advisable to discuss with the radiologist in order to identify the most representative area for sampling of the tissue. The path has to be planned ahead because the tract may have to be removed en-bloc with the final specimen. We usually do core-needle-biopsy because it leads to less contamination, smaller hematoma, less skin and soft tissue resection in the ultimate surgery. In the lower limbs, correction of any pre-operative clotting derangement and post-operative bed rest are helpful ways to minimize post-biopsy hematoma.

Histology of sarcoma is not easy to delineate. Sometimes, we may receive a report which is difficult to interpret. We may need to discuss the case with the pathologist and radiologist in person. In our hospital, we have regular Clinical-Pathological Conferences to



Wide margin resection of tumour with free flap coverage

reach joint decision on the subsequent management. In sarcomas, such as synovial sarcoma, clear cell sarcoma, and low grade fibromyxoid sarcoma, confirmatory molecular studies may be required.

Once sarcoma is confirmed, we proceed to systemic staging. A CT scan of the thorax and bone scan, as mentioned above, are the traditional investigation methods to assess any metastasis. A PET scan may be an alternative choice nowadays. Studies have found that PET scan is an effective way for systemic search but it is not yet proven that it can completely replace the conventional CT scan and bone scan. A PET-CT scan is considered to be a much more accurate method than a PET scan alone.

In the definitive management, different sarcoma subtypes may behave differently. Sarcomas such as embryonal rhabdomyosarcoma, primitive neuroectodermal tumour (PNET), should be treated with chemotherapy as the first line of treatment. Other sarcomas, such as synovial sarcoma and malignant fibrous histiocytoma, have to be resected with a wide margin, with or without adjuvant radiotherapy and chemotherapy. In order to provide optimum patient care, an orthopaedic tumour centre with experienced radiologists, pathologists, orthopaedic surgeons, radiotherapists and oncologists is the best place to handle these rare tumours.

#### References:

1. Wong CK. Lam YL. So YC. Ngan KC. Wong KY. Management of extremity soft tissue sarcoma after unplanned incomplete resection: experience of a regional musculoskeletal tumour centre. *Hong Kong Medical Journal*. 10(2):117-22, 2004 Apr.
2. Guidance on Cancer Service (Improving Outcomes for People with Sarcoma). National Institute for Health and Clinical Excellence. March 2006.
3. Ilaslan H. Schils J. Nageotte W. Lietman SA. Sundaram M. Clinical presentation and imaging of bone and soft-tissue sarcomas. [Review] *Cleveland Clinic Journal of Medicine*. 77 Suppl 1:S2-7, 2010 Mar.

# A Chat with Dr. Lam Ying Lee

Dr. Paul Koljonen / Dr. Margaret Fok

**Hi Dr. Lam, thanks for finding time for this interview. First of all, you have only joined our Department for about a year, so many of our junior colleagues may not know you too well (including myself) Why don't you take this opportunity to tell us something about yourself?**

Hi Paul, thanks for having me. Yes you are right. I've only been in this Department for one year and three months so a lot of things are new to me. I graduated in the class of 1987, and besides my earlier years of surgical elective training, I had worked in the Department of Orthopaedics in Queen Elizabeth Hospital all along. It was not until a position opened up here last year that I decided to transfer over.

**Dr. Lam, I understand that you have previously trained in the United States. Can you tell us a little bit about that?**

Between 1994 -1995 I spent time training in the US. First I spent three months in Davies Medical Center in California working with Dr. Harry Buncke, who is a plastic surgeon sub-specializing in microvascular surgery. At this clinic they had an enormous caseload and they did excellent microvascular work. I found it very interesting and challenging to learn some of the rarer methods of flaps that plastic surgeons use for reconstruction and wound coverage. At Davies, they also had excellent teamwork. As we know, microvascular reconstruction surgery can be very tiring. They had different surgeons doing the arterial and venous anastomoses in one operation. Then another team took over and did the tendon work, so surgeons were always fresh and could do their best work in each aspect.

I then spent the rest of my time at the Mayo Clinic, United States, working mainly on tumour cases. I worked with Dr. Michael Wood – who is an expert on hand and microvascular surgery, and Franklin Sim – who specializes in musculoskeletal oncology, sports and joint replacement. Life at Mayo was very productive, as these surgeons were quite the workaholics. The style of working was non-stop and I must say their fellows were extremely hard working. As a result they had really good training and exposure.

**What is the main difference between QMH and QEH?**

Well, in 2002, QEH restructured their department so that each specialist can pick two subspecialties to concentrate on. In my case, I devoted more than 70% of my time to orthopaedic oncology. In addition, I spent time doing microvascular surgery and a bit of general orthopaedics. In contrast, what I do here in QMH involves a lot more general orthopaedics.

**What is it about orthopaedic oncology that attracts you?**

Unlike most other orthopaedic subspecialties, orthopaedic oncology is not confined to any particular region or technique; rather it is a combination of all the subspecialties and their respective techniques.

For example, an osteosarcoma can occur in distal tibia, proximal femur, the humerus or even the spine. For all of these tumours the management principle is the same, but the techniques, knowledge and anatomy involved in the actual resection and reconstruction are very different. This presents a major challenge to my everyday work

**What's on the horizon for this subspecialty?**

A lot of the current research focuses on molecular studies on sarcomas. The implication is to develop target therapy drugs for these tumours. Having said that, much of this is still in the investigational phase. Clinical practice is not yet very popular.

As for actual surgical management, I'm interested in pelvic tumours and computer navigation systems for tumour resection. Improving the tendon-implant interface during reconstruction for knee mega-prostheses, and soft tissue coverage methods are topics of much importance. The concern is the ultimate stability and function of the limb.

# Department Research Day 2011

30 April 2011

The 6th Department Research Day was held on 30 April 2011. The aim of the meeting is to provide an opportunity for the basic scientists to meet up with the clinicians to exchange research ideas and to learn about the most recent updates.

The research postgraduate students also presented their work in the poster presentations. Best Poster Awards were awarded to the following out-standing presentations: Kuang Guan Ming, Tong Wing Yin Tommy, Sun Yi, Lam To Kam Cherry, Fong Henry, and Liu Cris. Congratulations!



## “Transcend the Past, Create the Future”

### The 50th Anniversary of the Department

The Department of Orthopaedics and Traumatology, University of Hong Kong, established on the 1st July, 1961, will celebrate its 50th Anniversary this year with a theme to “Transcend the past, Create the future”. A series of celebration activities will be arranged throughout the year, starting from July, 2011. One of our major events is the Orthopaedic Forum which will be held on the 18th August - 21st August. We have invited 15 world renowned academics to share with us their expertise. This will be a comprehensive scientific forum, covering all aspects of orthopaedics. Other activities will include Alumni reunion, community activities and mentorship programme. We shall keep you posted on our activities throughout the year at our website [www.hku.hk/ortho](http://www.hku.hk/ortho). We hope you shall enjoy our programme and share our joy and excitement.



50 years of Excellence –  
“Transcend the Past, Create the Future”



**The 8th Hong Kong International Orthopaedic Forum**  
18-21 August 2011

[www.hku.hk/ortho](http://www.hku.hk/ortho)

<b>In Ho Choi</b>	-South Korea	(Paediatric Orthopaedics)
<b>Peter Devane</b>	-New Zealand	(Joint Reconstruction)
<b>Chiew Siew Fong</b>	-Singapore	(Nursing)
<b>Freddie Fu</b>	-USA	(Sports & Arthroscopic Surgery)
<b>A Seth Greenwald</b>	-USA	(Joint Reconstruction)
<b>James Hui</b>	-Singapore	(Paediatric Orthopaedics)
<b>Shinichi Kikuchi</b>	-Japan	(Spine Surgery)
<b>Seung Ho Kim</b>	-South Korea	(Sports & Arthroscopic Surgery)
<b>Shoichi Kokubun</b>	-Japan	(Spine Surgery)
<b>Hubert LaBelle</b>	-Canada	(Spine Surgery)
<b>Chuanju Liu</b>	-USA	(Basic Science Research)
<b>Pol Rommens</b>	-Germany	(Orthopaedic Trauma)
<b>Paul Taylor</b>	-UK	(Rehabilitation)
<b>Fu Chan Wei</b>	-Taiwan	(Hand and Microsurgery)
<b>Michael Yaszemski</b>	-USA	(Musculoskeletal Oncology)

The HK Academy of Medicine Conference Center



Department of Orthopaedics and Traumatology, The University of Hong Kong  
香港大學矯形及創傷外科學系





## Tips from our Allied Health

### Amputee Running

Mr. Kenneth Wong


Prosthetic & Orthotic Department  
Hong Kong West Cluster

Tumours are one of the causes that may result in amputation. Amputees may suffer not only from the body impairments, but also a certain extent of disabilities. However, in most cases, amputees suffering from tumour can still undertake a lot of outdoor activities with the appropriate prosthesis. They would be able to move with prostheses of different cadences and can overcome different environmental barriers. Once the amputee can participate in more activities they are interested in, their body impairment will not be regarded as disabilities.

In the modern world, an amputee's expectation that prosthesis can provide a perfect natural replacement for a human limb is unrealistic. However, expectations for functional perfection of prostheses are increasing with the development of advanced technologies. New prosthetic technologies such as microprocessor assisted component or the advanced design on the mechanical prosthetic joint can provide greater stability and functional ability of the amputee. The silicone liner promotes maximum stability of the soft tissues and delivers the greatest cushioning of bony prominence and sensitive tissue.



Prosthetists are responsible for providing patients not only with the most appropriate prosthesis, but also adequate training in its use so as to obtain optimum cosmetic satisfaction, comfort and functional results for the amputee.



Modern prosthetic design can facilitate amputees to overcome their disabilities

## Our Postgraduate Students

### Orthopaedic Research Society

#### Annual Meeting 2011

Mr. Tong Wing Yin

Having the chance to attend and to give a talk at the prestigious 2011 Annual Meeting of the Orthopaedic Research Society in Long Beach California widened my horizon in terms of career and science. My greatest challenge was delivering my research to a few hundred people in minutes. Today's scientists must get their messages across quickly and succinctly as people could access new findings everyday, and thousands of different research projects are presented in one meeting, why should people care? There were some very comprehensive research projects presented at the conference, but the talks presented by energetic interesting speakers made the greatest impact on the audience. To me it was clear that passion empowered them, giving these researchers the prerequisite brilliant ideas as well as the eagerness to share. I plan to humbly start living a passionate research life.

The second lesson I learned is that the world of science is too big. It was mind blowing to stand at the center of a giant warehouse covered with countless scientific posters, while presentations were going on in every hall. Every poster and presentation told stories of people struggling to answer questions, about everything from basic science to clinical



Me, Kelvin Yeung, Victor Leung, Vivian Tam and Michael To's family (from left to right)

applications. However, compared to the size of the world of science, the resources expended are not enough. Although several teams may conduct research on the same thing, there are always new questions to be asked and new perspectives to be considered. It is normal that the golden rules of today be replaced by the knowledge of tomorrow, changing the landscape of the world. Living in a convenient city like Hong Kong could trap me into accepting the status quo instead of opening my eyes to the possibilities of the future. One of my teachers used to say, "We need more questions, not answers; more ideas, not solutions". Perhaps as a scientist I really should start every day by asking, "What question should I ask today?"

The chance to attend overseas conferences seems like a waste if one doesn't make the time to sightsee. The California sunshine was a pleasant change from the cold Hong Kong weather. After the conference, I went to downtown LA with my supervisors and colleagues, visiting Universal Studio and Hollywood. The food was great, the weather was fine, life was good, and the conference was a perfect experience.

## My Exchange Program at the University of Texas at Arlington


Ms. Yonnis Choy



No one can 'know-it-all'. People need to share their knowledge and co-operate with others to maximize their efficiency and enhance quality of output. Likewise in scientific research, we need people from different backgrounds, such as medicine, chemistry and biology, to collaborate and share different ideas and knowledge. The fusion of knowledge usually brings new insight to the field, and I believe this is the beauty

of an exchange programme.

I had a great experience as a research student working in the USA. I am so pleased that my supervisors, Dr. Josephine WY Ip and Dr. Kelvin WK Yeung provided me with such an opportunity to participate in this collaborative project with Dr. Jian Yang of the Department of Bioengineering at the University of Texas at Arlington. During my three months in Dr. Yang's laboratory, I was not only learning about the knowledge and techniques related to my



My lab partners at Arlington

research project, but also making friends. I wish I could go to visit them again in the future. I know this is also one of the greatest bonuses in an exchange programme.

Before the exchange programme, I only focused on the biological characterizations and not the fabrication processes of the biomaterials. Fortunately, I was able to learn about such processes when I was in the USA and I started from the basics. With the help of Dr. Yang's PhD student, Richard Tran, I synthesized my first biomaterial. Like alchemists, we mixed different kinds of monomers, observing as they reacted with each other to form different biomaterials. This was a completely new experience for me, and it was exciting and nerve-wracking.



Dr. Jian Yang (2nd from the right)

Apart from research work, I was lucky enough to experience Thanksgiving, Christmas and New Year's Eve, days which are very important to Americans. Richard invited me to join his family's celebration on Thanksgiving Day. A juicy roast turkey, cranberry sauce and sweet pumpkin pie are typical Thanksgiving dishes I tried that day. I am grateful to Richard for inviting me, and I will miss his nice family, the food and his three lovely Chihuahuas!

The exchange programme was a great experience and I would encourage others to join if such opportunity comes along.



# Announcements

## The 184th Congregation of the University of Hong Kong

**Prof. John Leong** was awarded the **Doctor of Science *honoris causa*** on 22 Mar 2011. The University's honorary degree is the highest accolade it can bestow on an individual, and is also one of its oldest and most cherished traditions.



Prof. Leong receiving the Honorary Degree at the 184th Congregation


## Hong Kong West Cluster's Outstanding Team Award 2011

**Hong Kong West Geriatric Hip Fracture Clinical Pathway Team** (Team Leader: **Dr. TW Lau** of **Division of Orthopaedic Trauma**)

## AO Spine East Asia

**Dr. Vivian Tam** was awarded the **AO Spine East Asia**

**Research Grant Award** which is supported by the AOSpine East Asia Council. This award was presented at the Global Spine Congress in Barcelona, Spain. The title of the proposal is "**Determination of the importance of the source of iPSCs for differentiation in the IVD niche**". The co-investigators are **Prof. KMC Cheung**<sup>1</sup> and **Dr. Danny Chan**<sup>2</sup> (Department of Orthopaedics and Traumatology<sup>1</sup> and Biochemistry<sup>2</sup> of HKU)



Dr. V. Tam and Dr. D. Samartzis received their awards at the Global Spine Congress in Barcelona

## AOSpine

**Dr. Dino Samartzis** was awarded Hansjord Wyss Award from AO Spine to address "**Metabonomics**" of lumbar intervertebral disc degeneration. It is a very novel field related to the spine and it can add a new phenotype from a metabolic perspective to the aspect of disc degeneration, which can later even be used for our genome-wide association studies (GWAS) analysis etc.

## Hong Kong Society for Surgery of the Hand (HKSSH) Annual Congress

**Dr. Yip S L, Choy WM**<sup>1</sup>, **Dr. Yang J**<sup>2</sup> and **Dr. Ip WY**<sup>1</sup>, Department of Orthopaedics and Traumatology, The University of Hong Kong<sup>1</sup> and Bioengineering, University of Texas at Arlington<sup>2</sup> were awarded the **HKSSH Best Paper Award** in the HKSSH Annual Congress in late March 2011

for the paper entitled: "**New biodegradable nerve conduit, Crosslinked Urethane-doped Polyester Elastomers (CUPEs), in rats**".

## Society of Photographic Instrumentation Engineers (SPIE) Medical Imaging conference

Kang X<sup>1</sup>, Taylor R H<sup>1</sup>, M Armand<sup>1</sup>, Otake Y<sup>1</sup>, Dr. WP Yau<sup>2</sup>, Dr. Cheung PYS<sup>2</sup> and Dr. Hu Y<sup>2</sup> were awarded the Cum Laude Best Poster Award in SPIE Medical Imaging conference. The title is "**Correspondenceless 3D-2D Registration Based on Expectation Conditional Maximization**".

The Johns Hopkins University, USA<sup>1</sup>, Department of Orthopaedics and Traumatology, HKU<sup>2</sup>

## GOODBYE

Dr. Pun Tze Shing has left the Department for private practice in April 2011

Ms. Angela Chan, our Nursing Officer, has retired from our Department in April 2011

## FORTHCOMING EVENTS

The 8th HK International Orthopaedic Forum will be held 18-21 Aug 2011 at the Hong Kong Academy of Medicine

For more information about Basic Microsurgery Course, please call Ms. Doris Lau at 2255 4581 or e-mail [lws835a@ha.org.hk](mailto:lws835a@ha.org.hk)

## EDITORIAL BOARD

Dr. Michael To

Dr. KC Mak

Dr. Margaret Fok

Department of O&T  
Queen Mary Hospital  
102 Pokfulam Rd  
Hong Kong  
Tel (852) 22554654  
Fax (852) 28174392